

SIQ
7.8

RATE ARTICLE

What's This?

Table of Contents ▼

Categories ▲

- Dentistry
- Oral Medicine
- Infectious Disease

Keywords ▼

ADVERTISEMENT

Case Report

A Novel and Minimally Invasive Approach Using the Root and Cervical Margin Flattening Procedure for Treating Gingival Recession: A Report of Four Cases

3

Kazunari Ando • Daiki Ando • Yuki Kojima

Published: July 22, 2024 DOI: 10.7759/cureus.65142

Peer-Reviewed

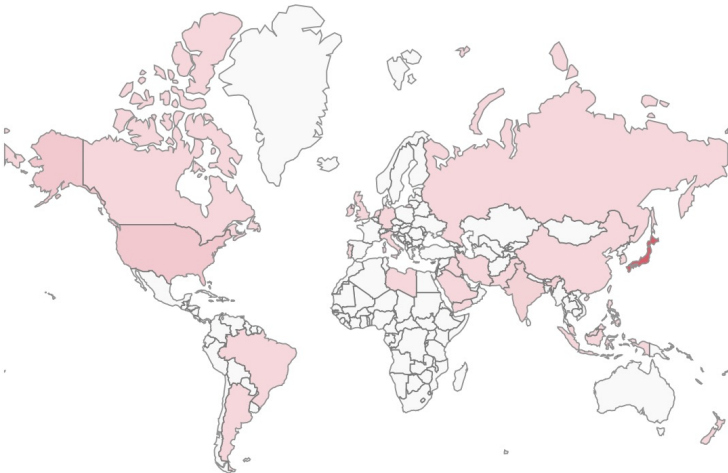
Cite this article as: Ando K, Ando D, Kojima Y (July 22, 2024) A Novel and Minimally Invasive Approach Using the Root and Cervical Margin Flattening Procedure for Treating Gingival Recession: A Report of Four Cases. Cureus 16(7): e65142. doi:10.7759/cureus.65142

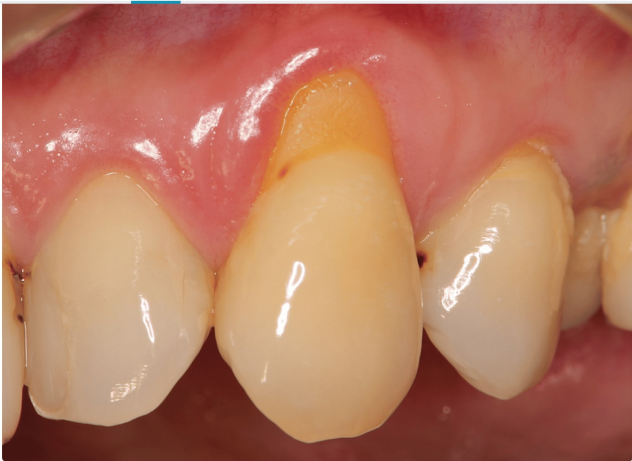

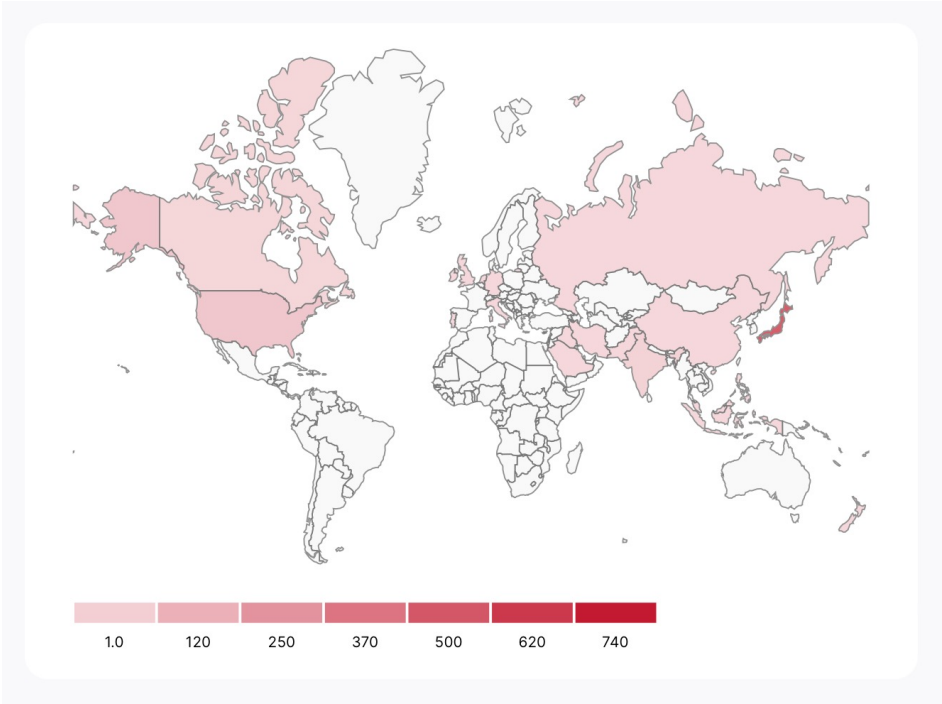
Figure 1: Preoperative image in Case 1
Gums are inflammation-free, plaque control is good, and periodontal pockets are ≤ 3 mm.

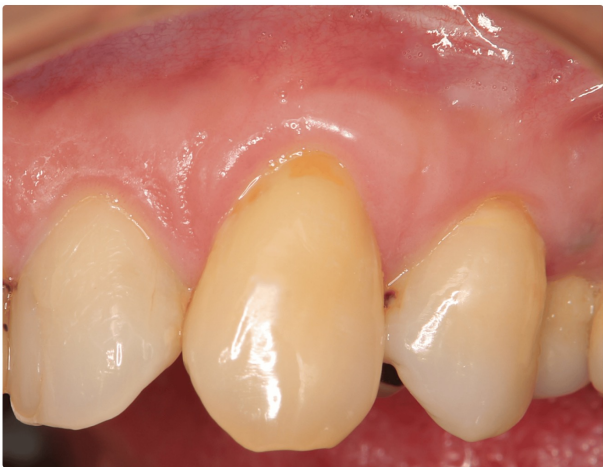
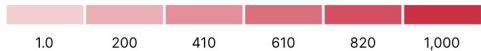
Figure 9: Postoperative image after 12 months in Case 1



公開されて日が浅いのですが論文読者が世界中に広がってます。



Total Article Reads

Article reads consist of online article views and PDF downloads. Cureus data is delayed by 24 hours and PMC data is delayed by approximately one month.

832

Want more reads?
Total Article Reads

780
Cureus
Article Views

52
Cureus
PDF Downloads

0
PMC
Article Views

0
PMC
PDF Downloads



• 応援宜しくお願いします